Inflammatory Diseases Of Bone

Osteitis is a localized inflammation of bone with no progression through the marrow spaces. particularly that associated with infected sockets.

Osteomyelitis is a more extensive inflammation of the interior of the bone involving and typically spreading through the marrow spaces.

Periostitis inflammation of the periosteal surface of the bone and may or may not be associated with osteomyelitis.

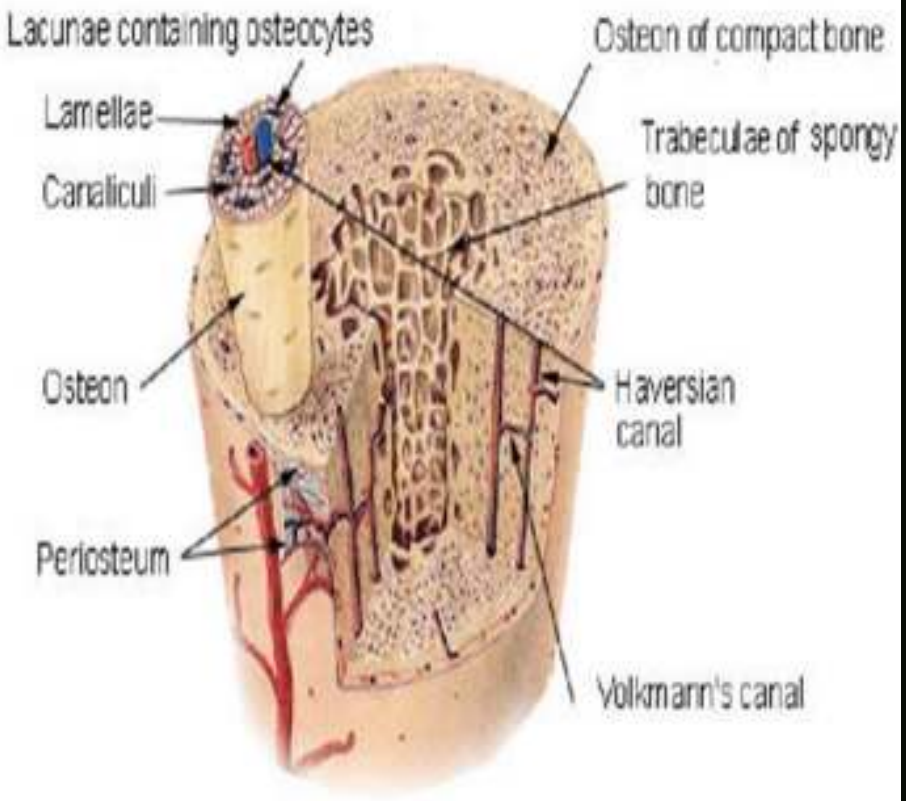
Lacunae containing osteocytes
Lamellae
Canaliculi
Osteon
Periosteum
Osteon of compact bone
Trabeculae of spongy bone
Haversian canal
Volkmann's canal

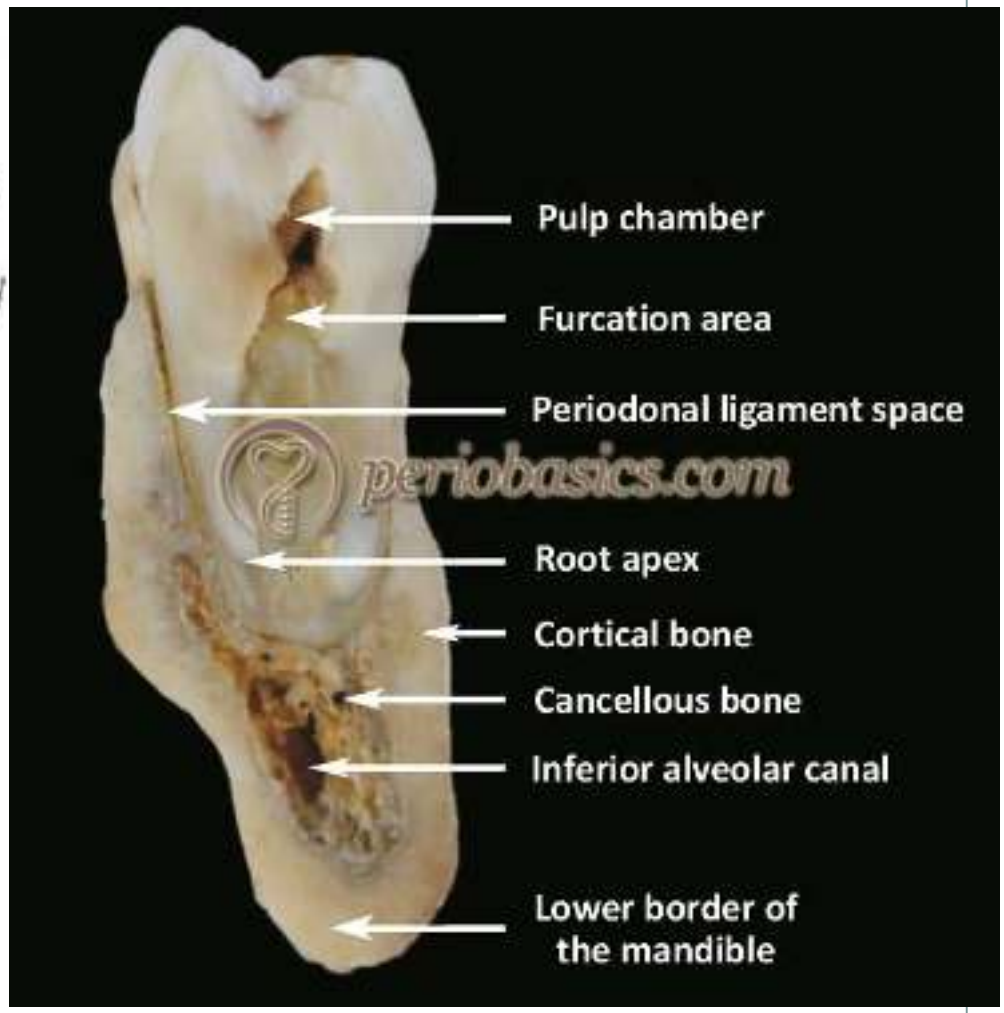
Pulp chamber
Furcation area
Periodonal ligament space
periobasics.com
Root apex
Cortical bone
Cancellous bone
Inferior alveolar canal
Lower border of the mandible

Acute Osteomyelitis. Ill-defined area of radiolucency of the right body of the mandible.

Acute Osteomyelitis with Sequestrum. Radiolucency of the right body of the mandible with central radiopaque mass of necrotic bone

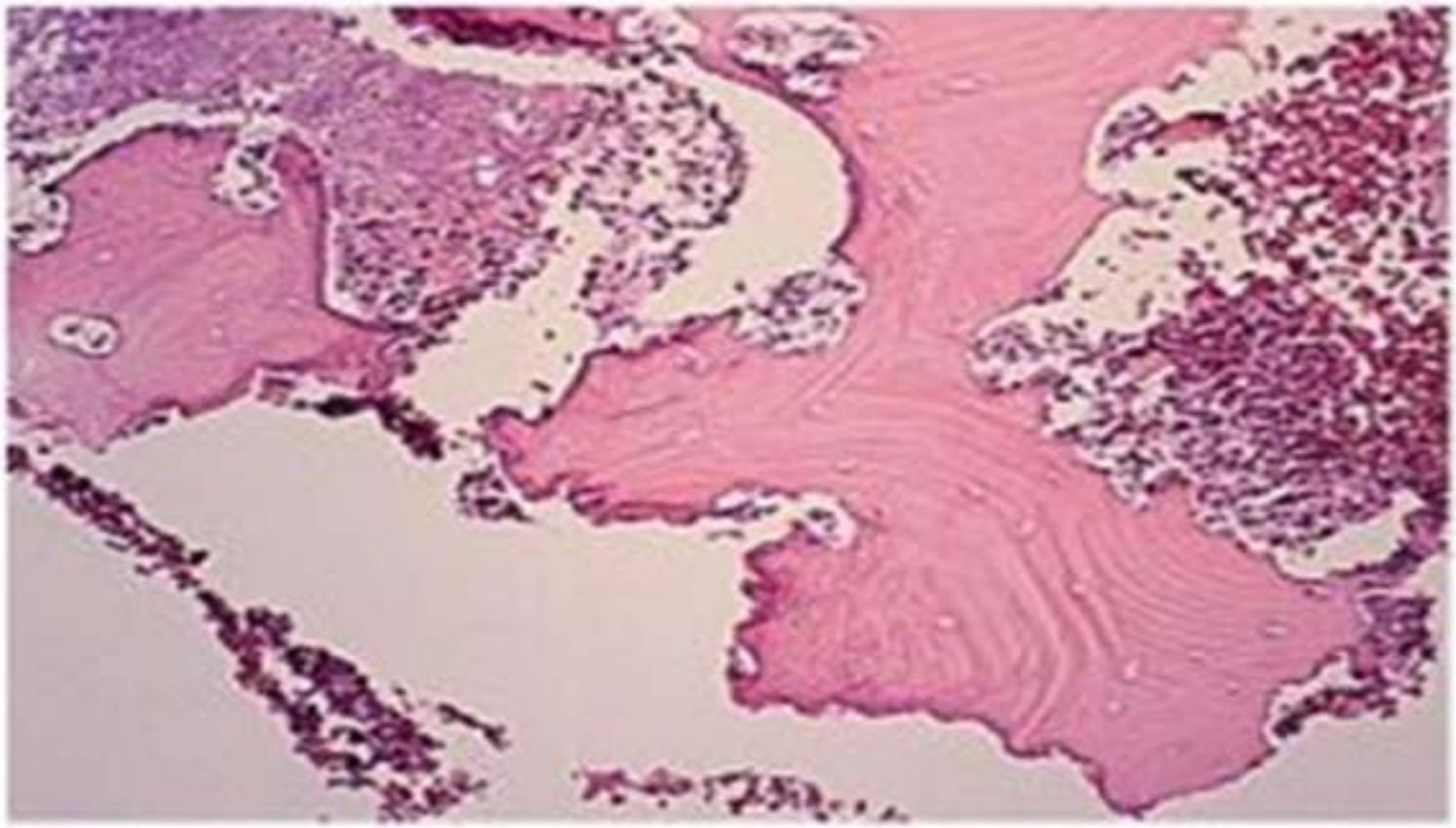

Acute Osteomyelitis. Nonvital bone exhibits loss of the osteocytes from the lacunae. Peripheral resorption, bacterial colonization, and surrounding inflammatory response also

Acute osteomyelitis

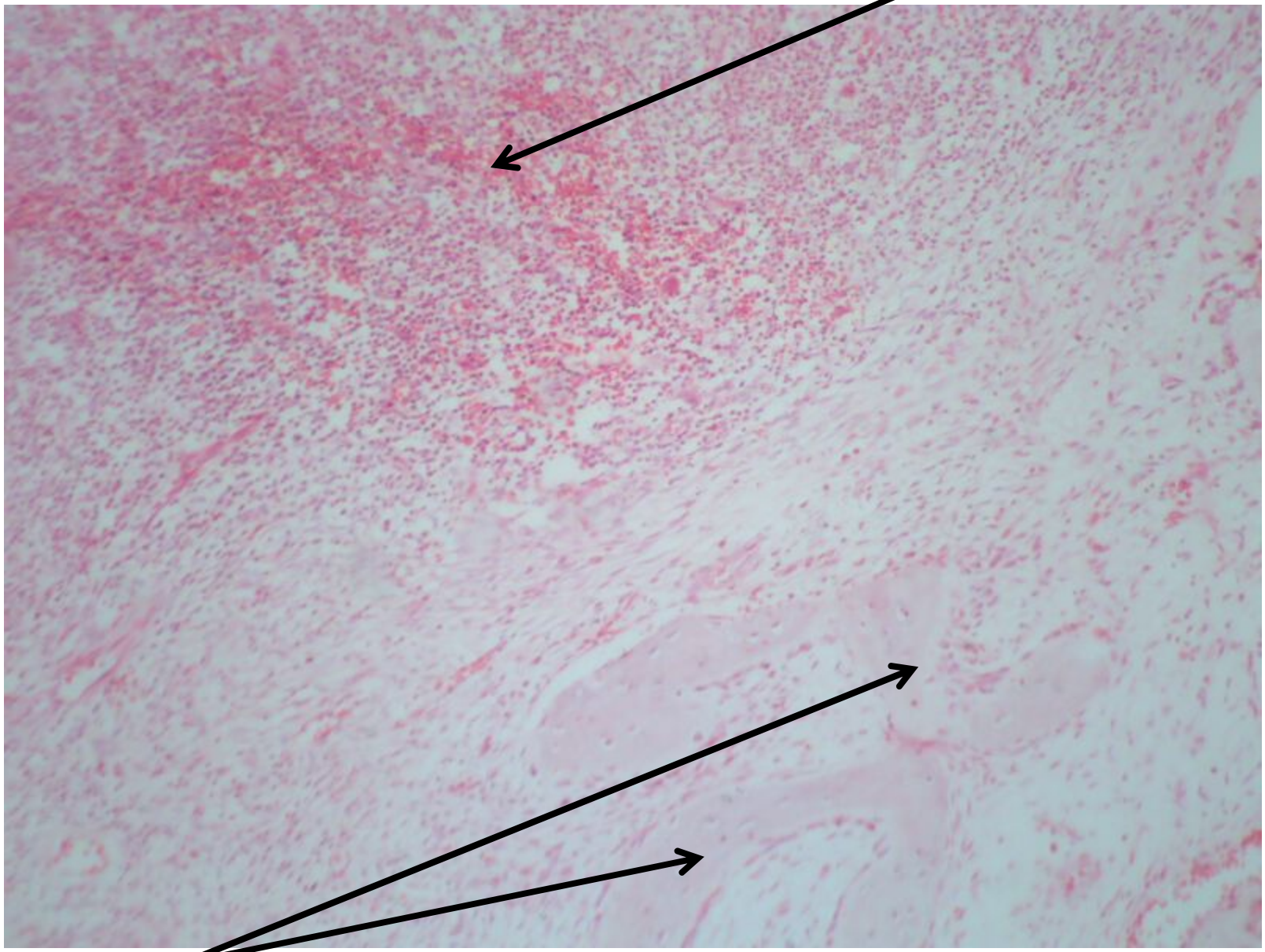

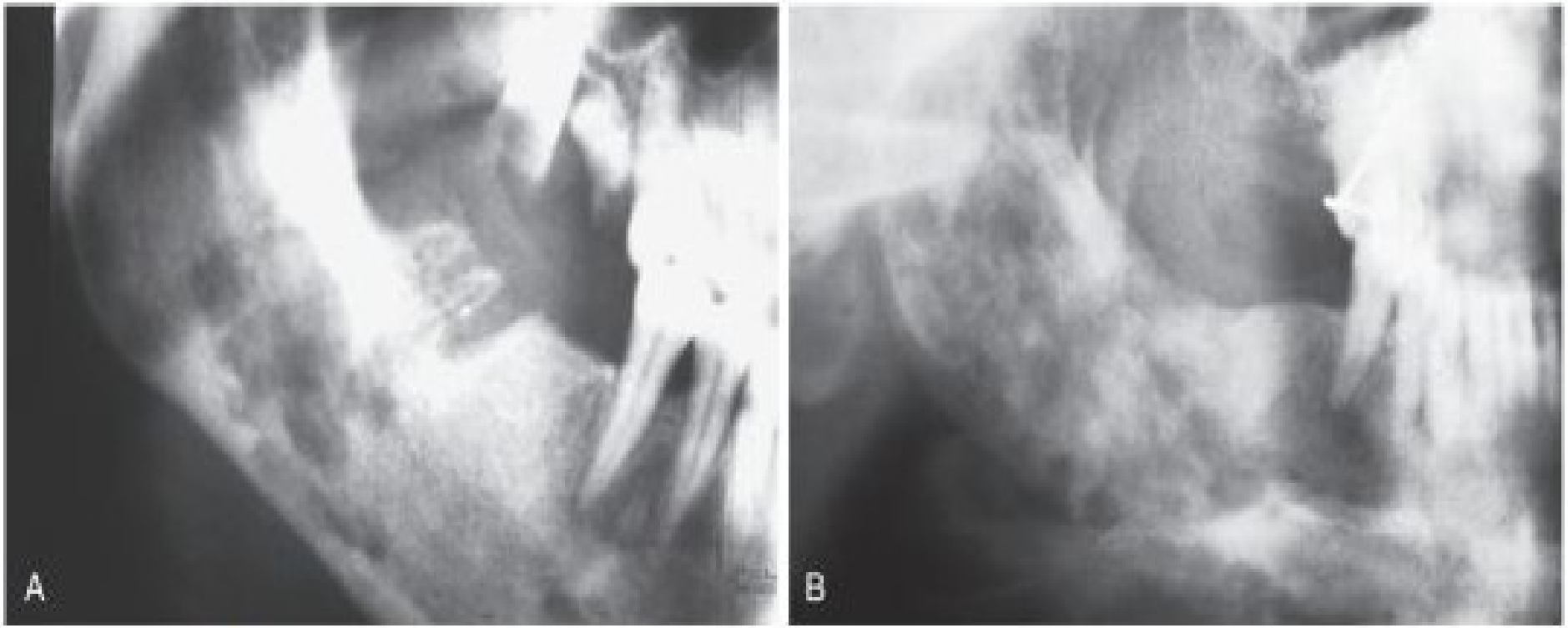

Chronic Osteomyelitis. A, Ill-defined area of radiolucency of the right body of the mandible adjacent to a recent extraction site. B, After the initial intervention, the patient failed to return for follow-up because of lack of significant pain. An enlarged, ill-defined radiolucency of the right body of the mandible was discovered 2 years after the initial surgery.

Chronic osteomyelitis

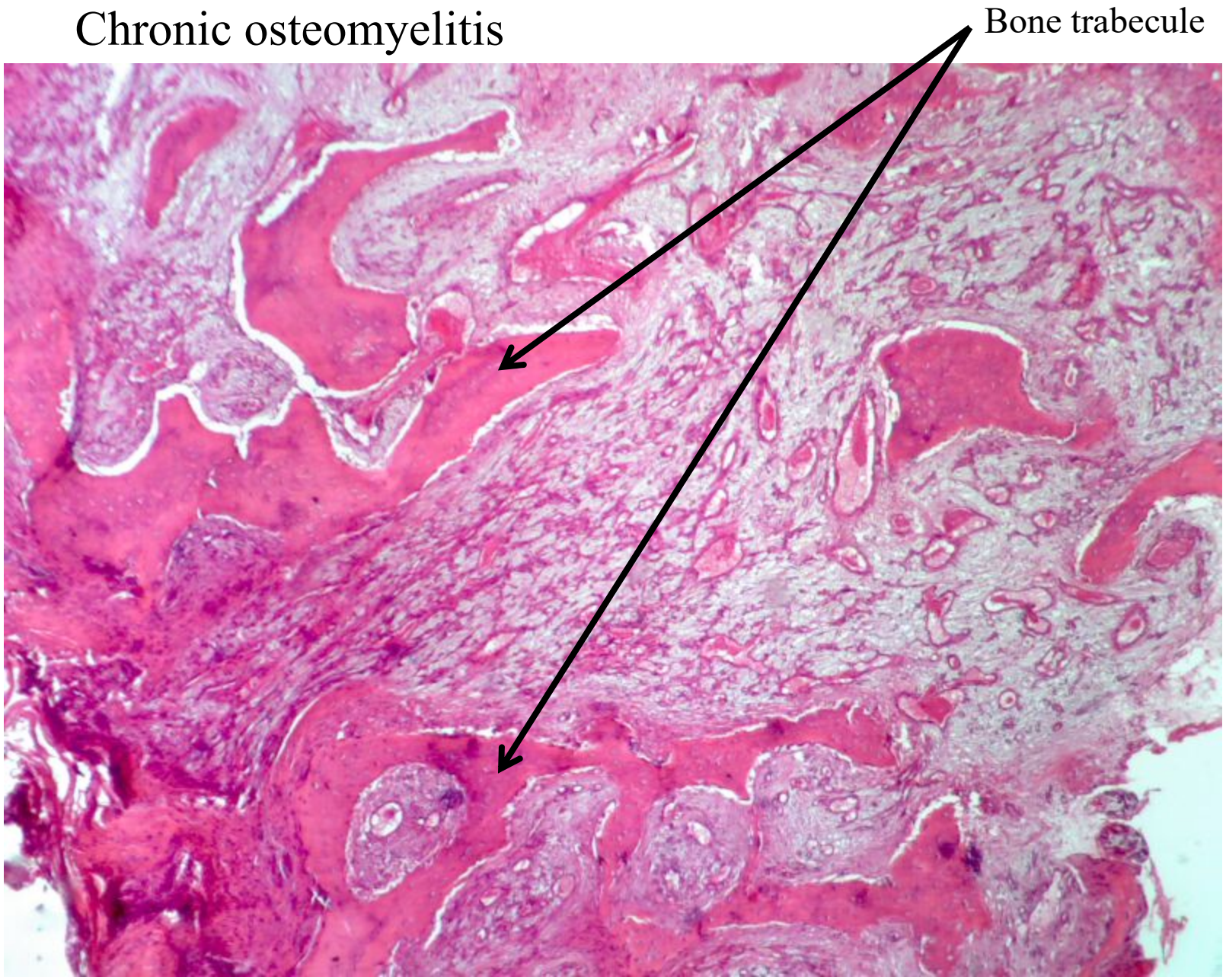

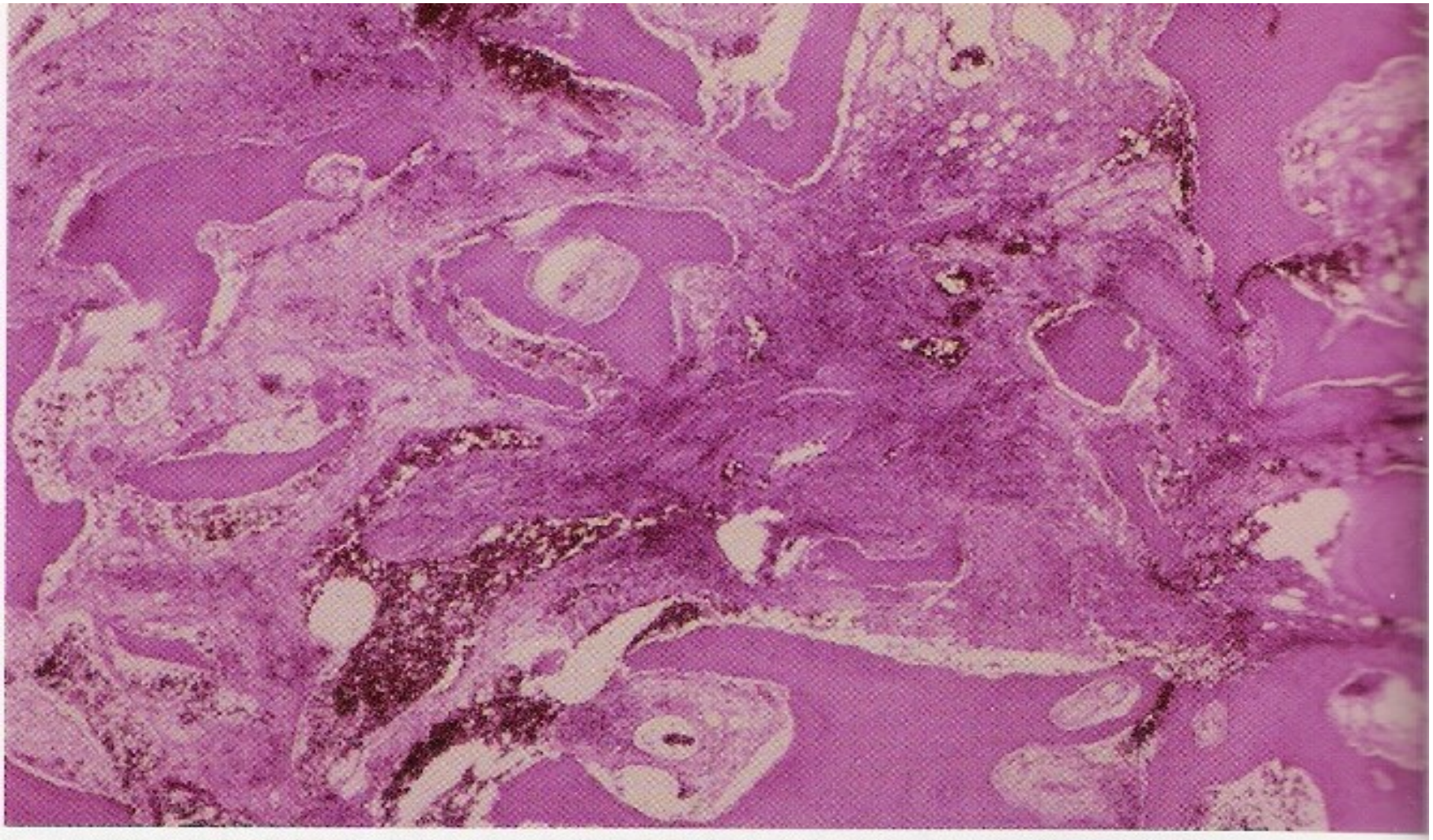

Figure 3-51 ◆ **Chronic osteomyelitis.** Chronically inflamed and reactive fibrous connective tissue filling the intertrabecular spaces.

Sequestrum (Dead bone)

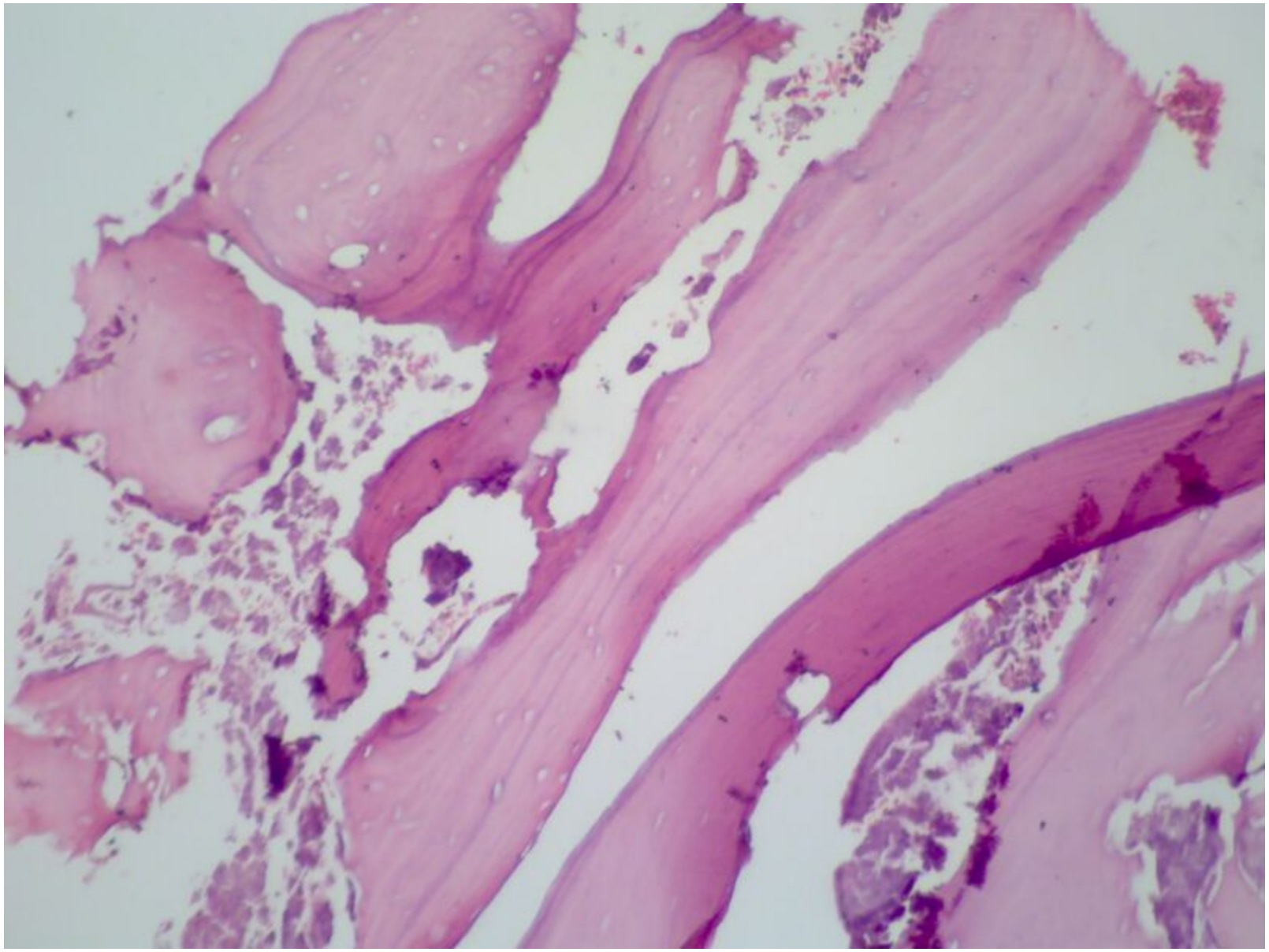

Focal sclerosing osteomyelitis

Focal sclerosing osteomyelitis. Increased areas of radiodensity surrounding the apices of the nonvital mandibular first molar.

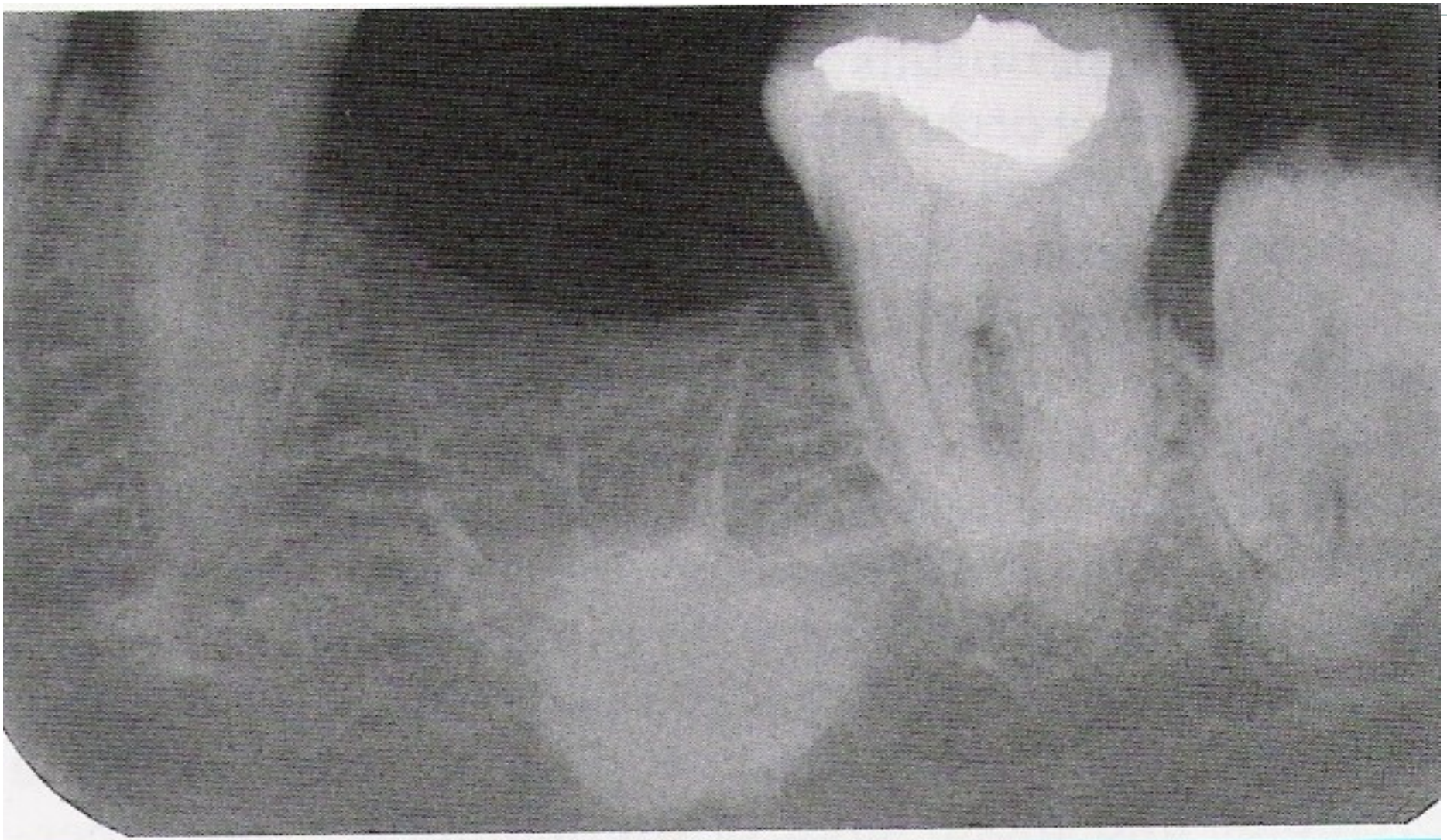

Bone Scar. Residual area of increased radiodensity in the area of extraction of the mandibular first molar.

Chronic Osteomyelitis with Proliferative Periostitis:

(Garré's Osteomyelitis)

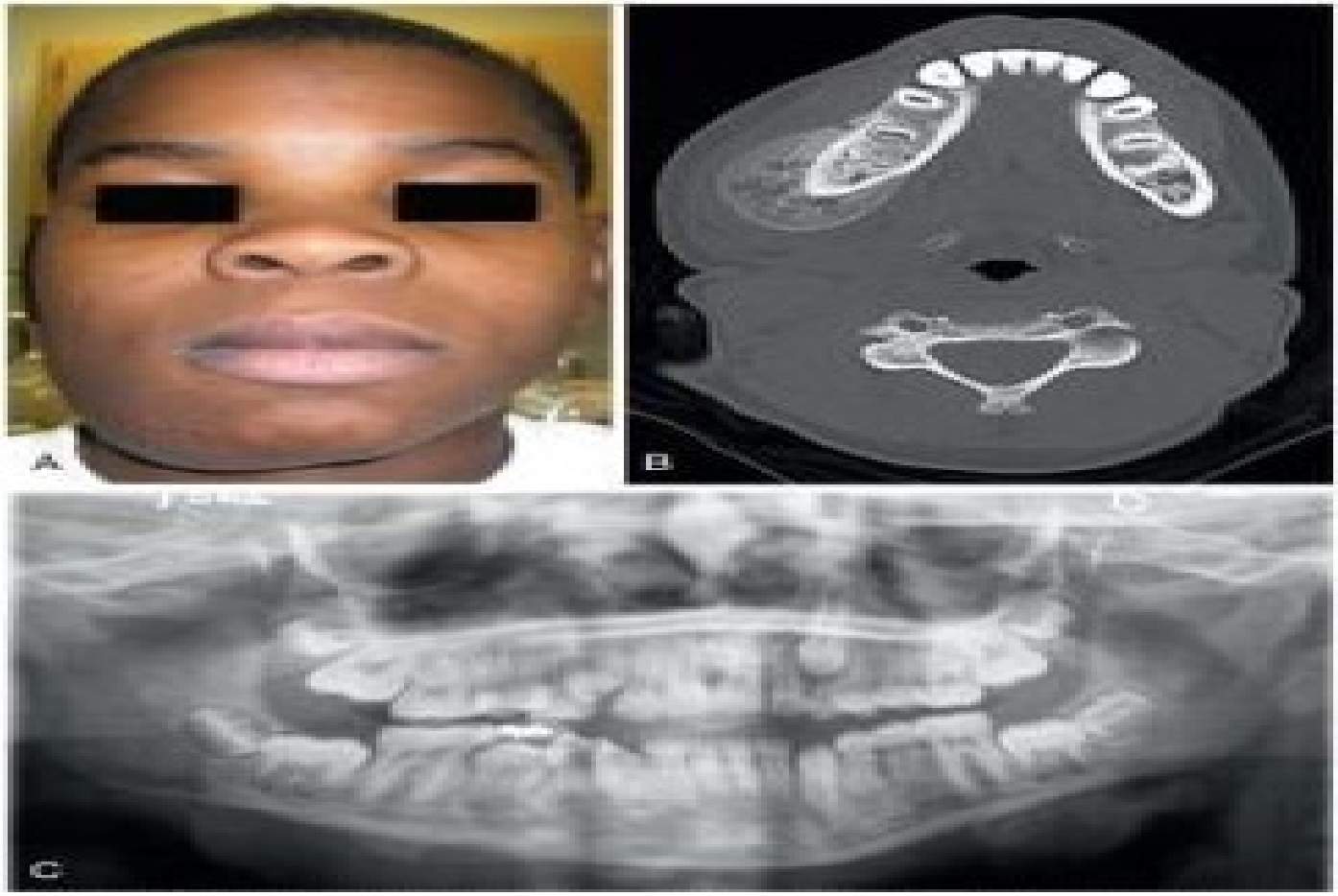

Proliferative Periostitis. A, Firm swelling of the lateral and inferior border of the right mandible that arose after traumatic injury. B, Computed tomography (CT) image demonstrating new periosteal bone growth with onionskin laminations. C, Panoramic radiograph exhibiting new periosteal bone formation along the right inferior border of the mandible.

Figure 3-55 • Proliferative periostitis. Radiopaque laminations of cortical bone parallel the cortex adjacent to inflammatory process of the mandibular bicuspid. (Courtesy of Dr. William

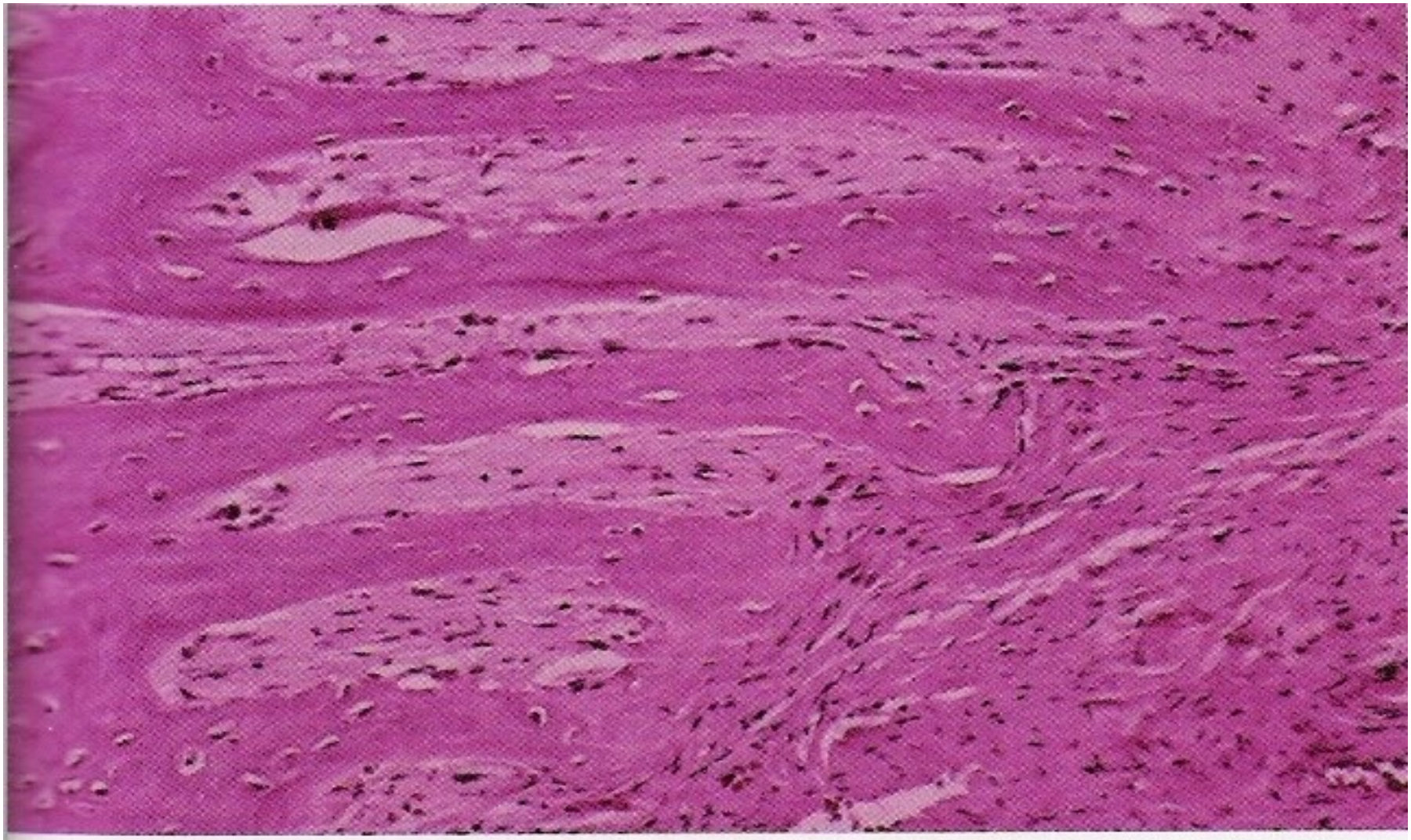

gure 3-56 • **Proliferative periostitis.** Cellular and reactive vital one with individual trabeculae oriented perpendicular to the rface.

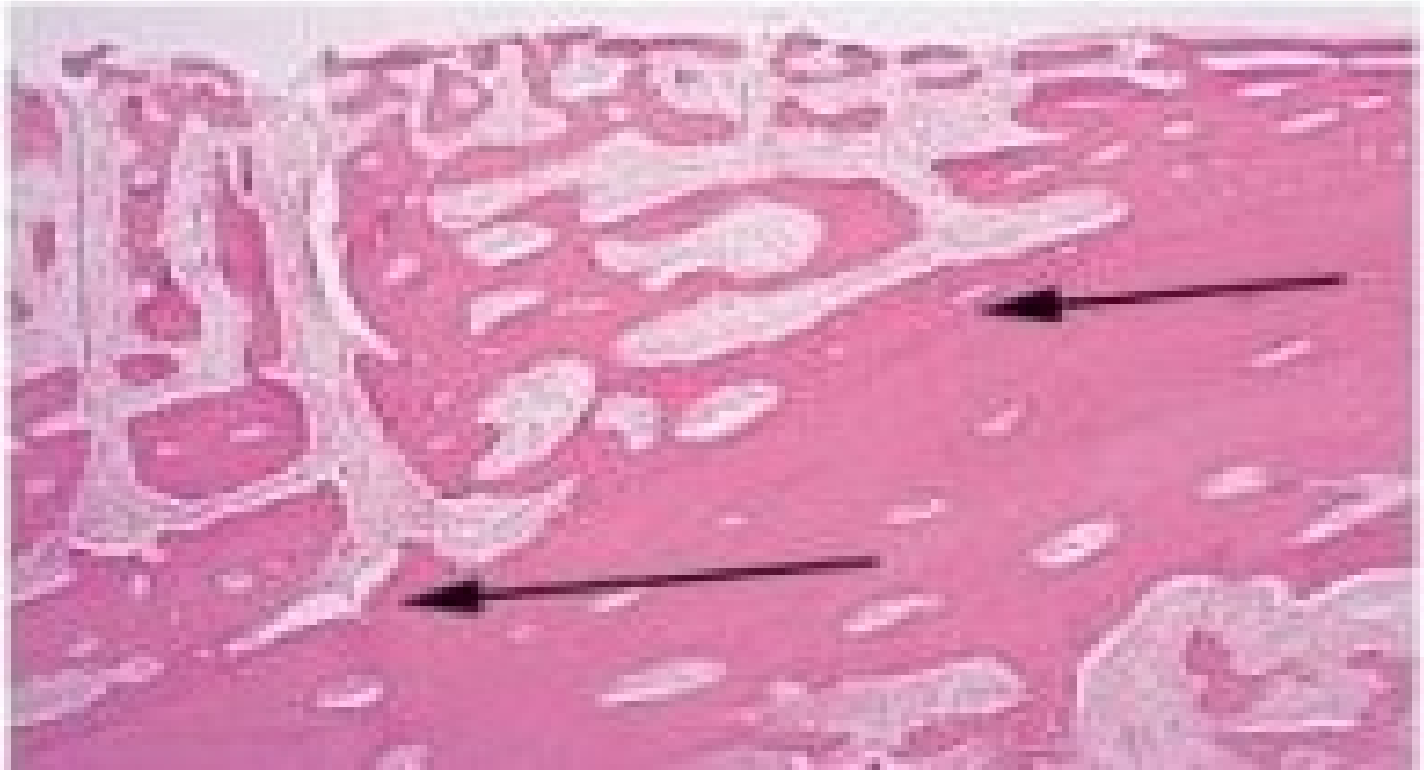

Proliferative Periostitis. Interconnecting trabeculae of new bone formation (top left) extending from the original cortical surface

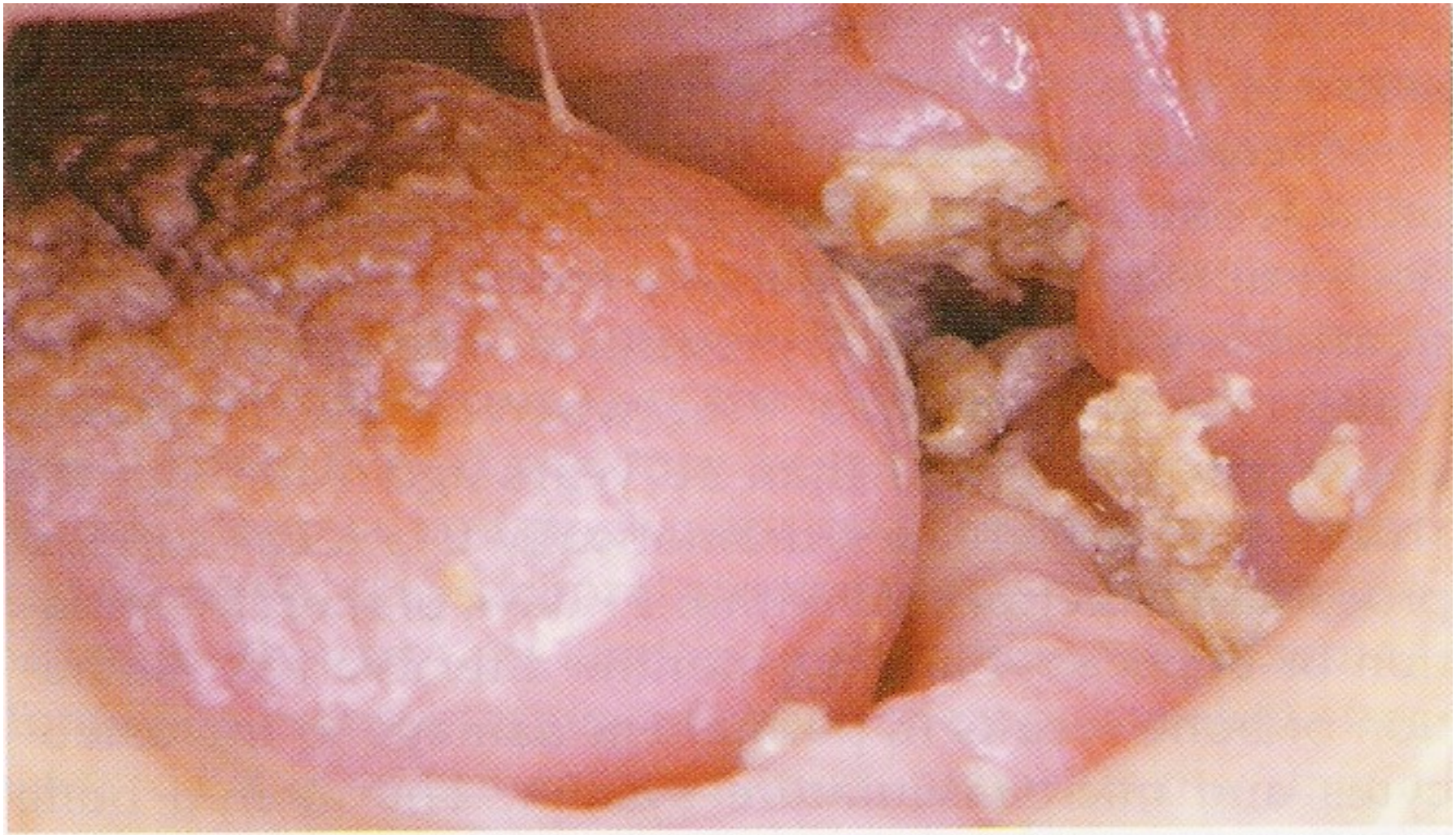

Figure 8-25 • **Osteoradionecrosis.** Ulceration overlying left body of the mandible with exposure and sequestration of superficial alveolar bone.

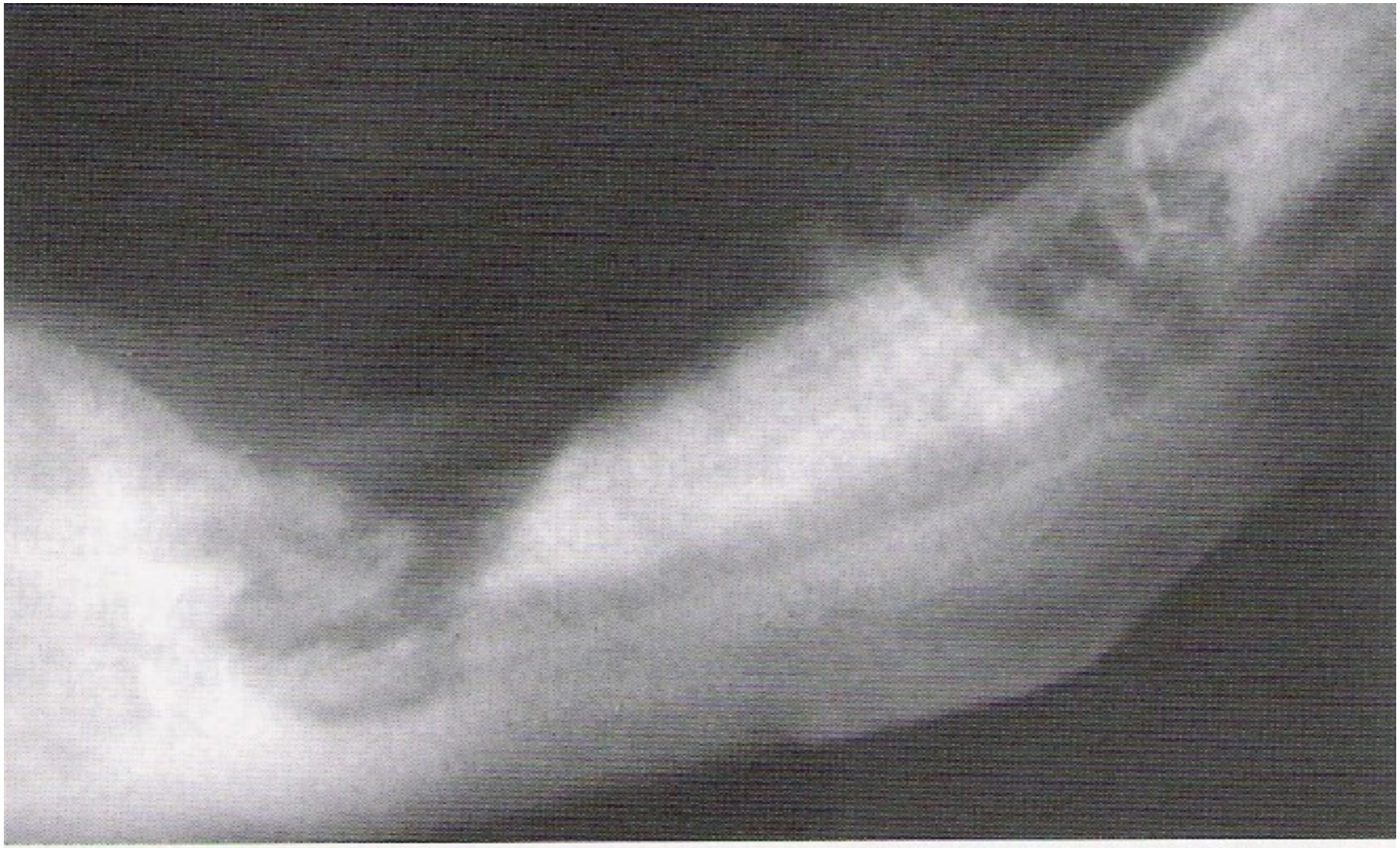

Figure 8-26 • **Osteoradionecrosis.** Multiple ill-defined areas of radiolucency and radiopacity of the mandibular body.

Figure 8-27 • **Osteoradionecrosis.** Same patient as depicted in Figure 8-25. Note fistula formation of the left submandibular area resulting from osteoradionecrosis of the mandibular body.

Osteoradionecrosis of the lingual mandible precipitated by trauma.

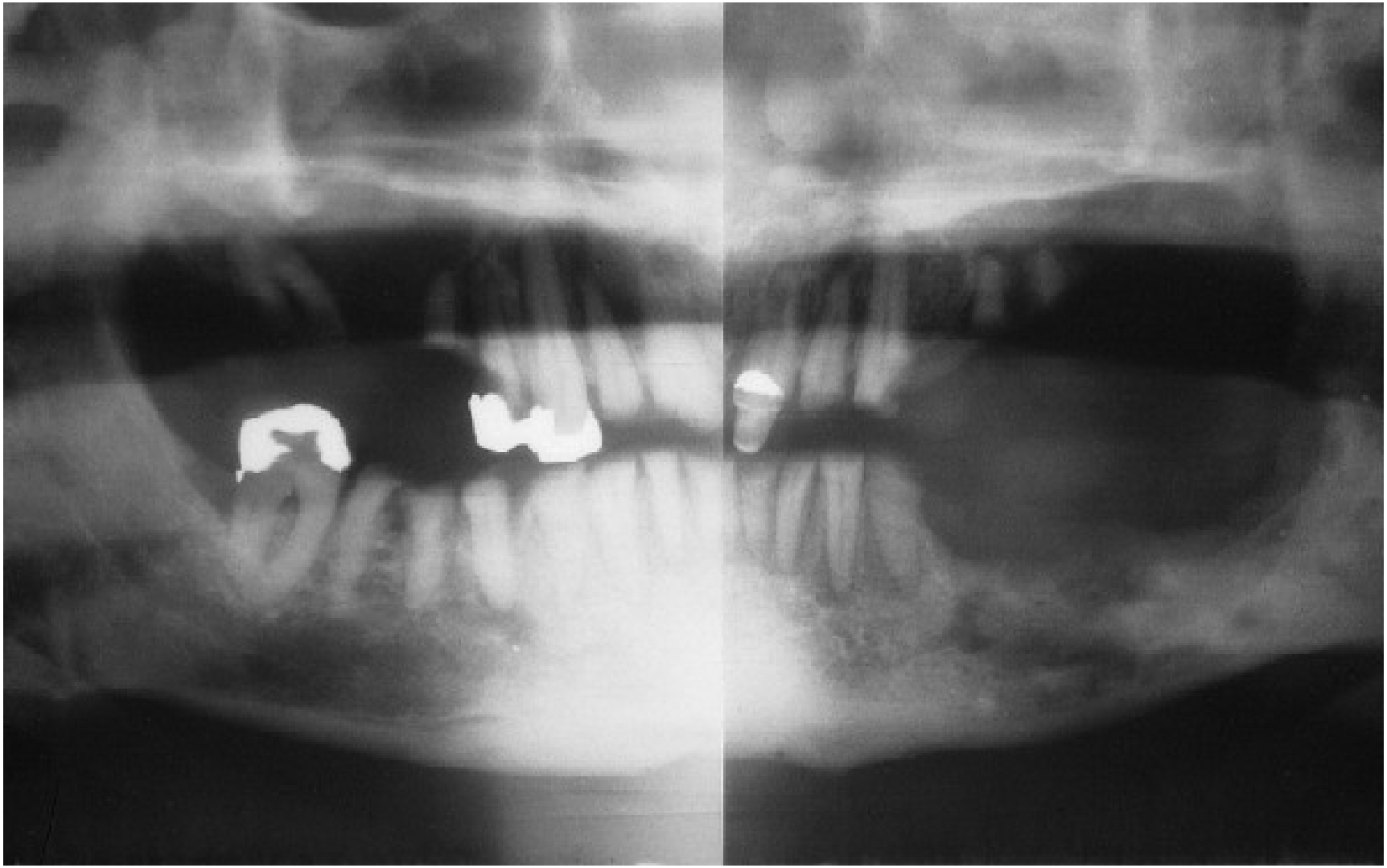

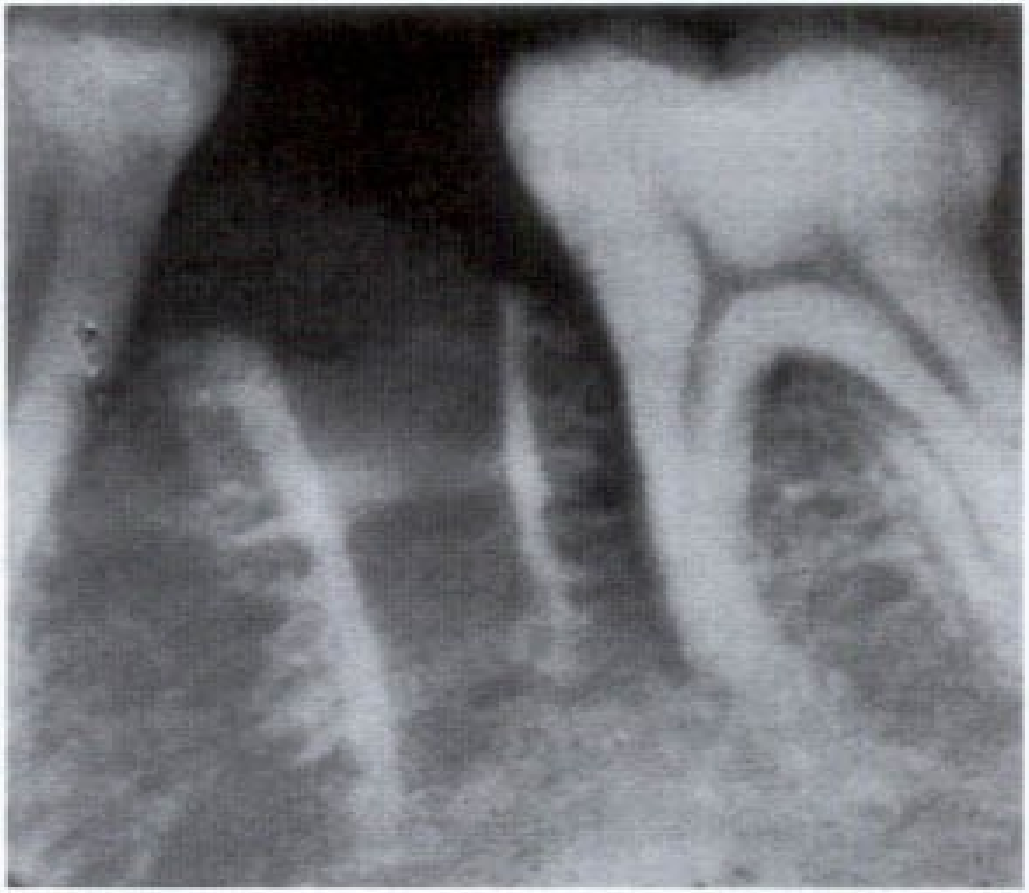

Sequestration in a severe dry socket. Almost the whole of the lamina dura and attached trabeculae have become necrotic, forming a sequestrum. Healing is delayed while the sequestrum remains in place. Most dry sockets are not associated with sequestration, or with only small sequestra.

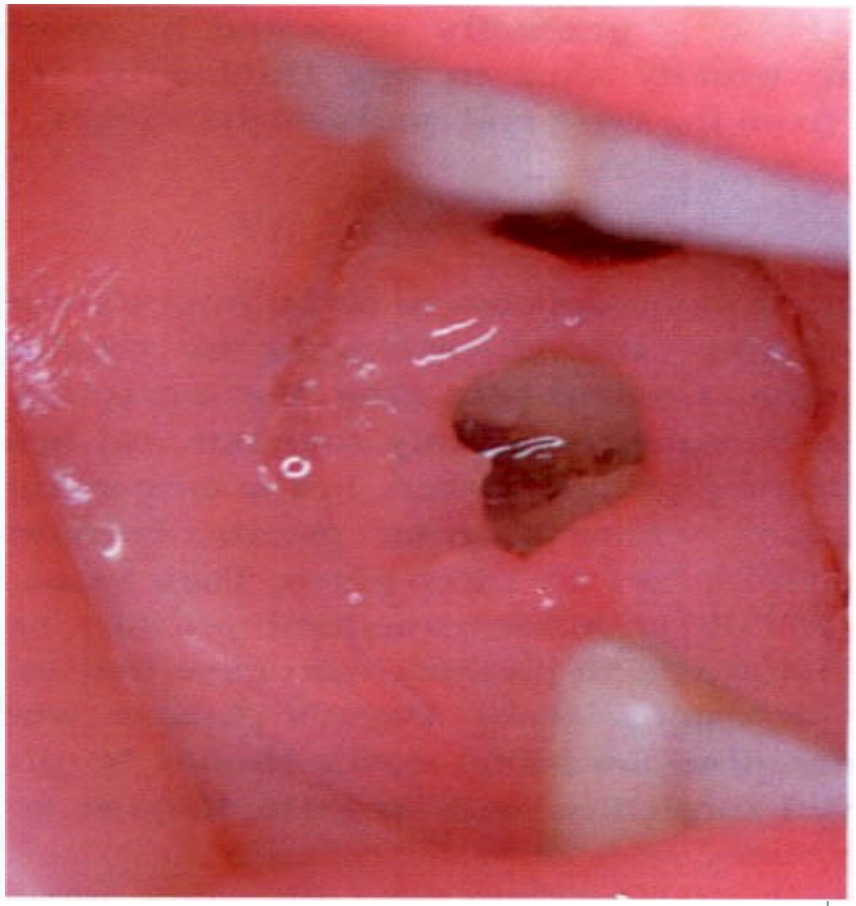

Dry socket. Typical appearances of chronic alveolar osteitis; the socket is empty and the bony lamina dura is visible.

ACUTE SUPPURATIVE OSTEOMYELITIS

HISTOLOGY

- Submitted material for biopsy predominantly consists of necrotic bone & is diagnosed as sequestrum



- Bone shows:
  - Loss of osteocytes from lacunae.
  - Peripheral resorption
  - Bacterial colonization.
  - Acute inflammatory infiltrate consisting of polymorphonuclear leukocytes in haversian canals & peripheral bone.

Acute O.M.

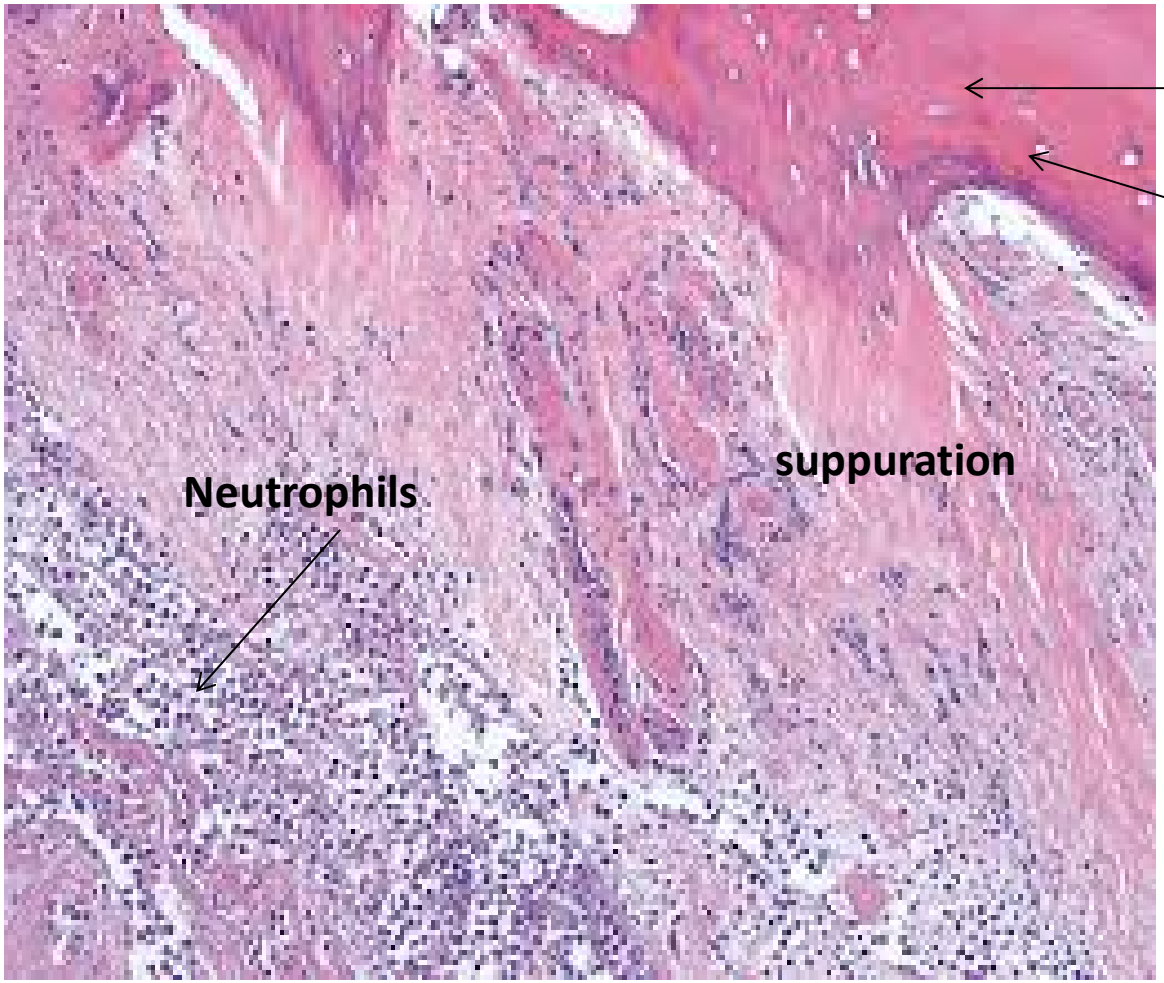

Dead bone (sequester)

Empty lacunea

Acute O.M.

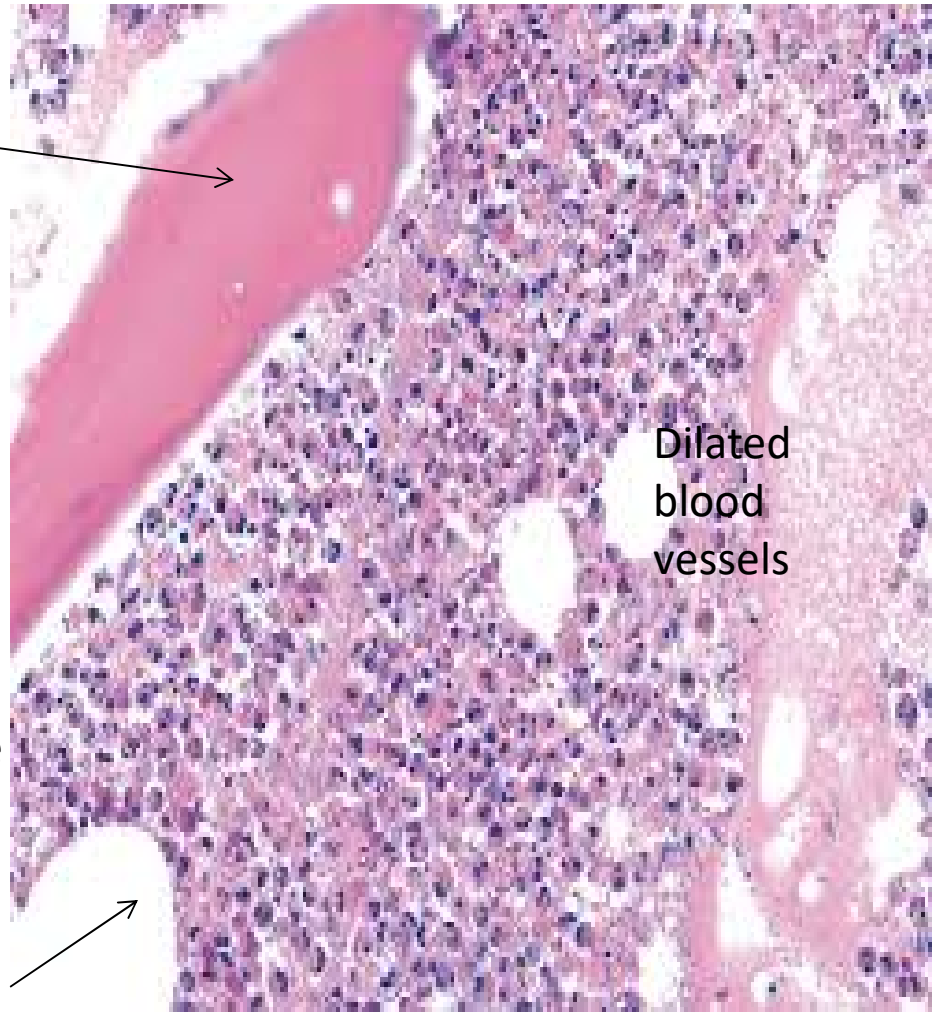
sequestrate
Dilated blood vessels
Neutrophils infiltrate
Fat droplets

Diffuse sclerotic O.M.

Necrotic bone surrounded by fibrous tissue

Scanty marrow spaces

Bone sclerosis and remodeling

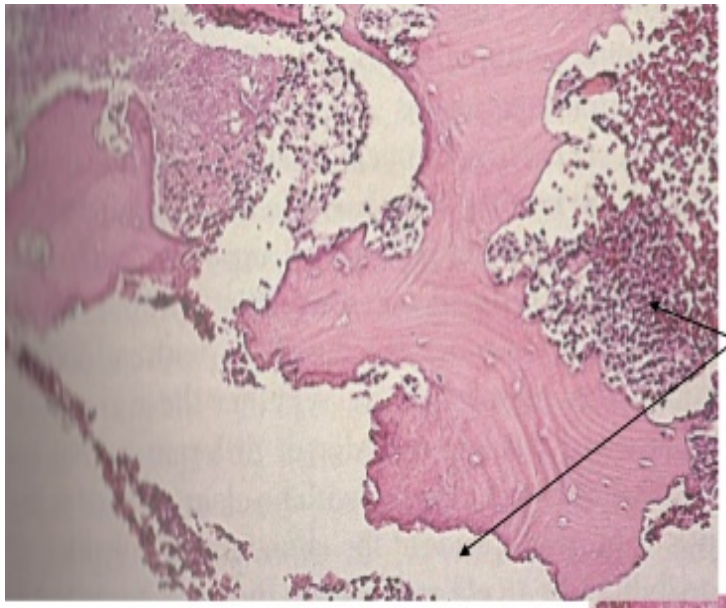

Acute Osteomyelitis

Nonvital bone shows absence of osteocytes in lacunae.

Peripheral resorption, bacterial colonisation & inflam. Response.

Chronic Osteomyelitis

Chronic inflamation & reactive fibrous CT filling intertrabecular spaces.

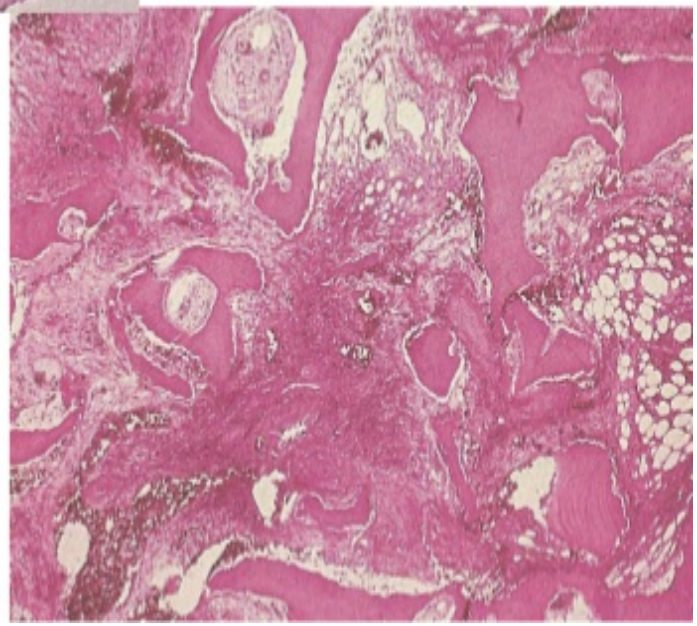

Garres O.M.

Fibrous tissue
With chronic
inflammatory cells

Newly formed
Bone trabeculae
Arranged in
perpendicular

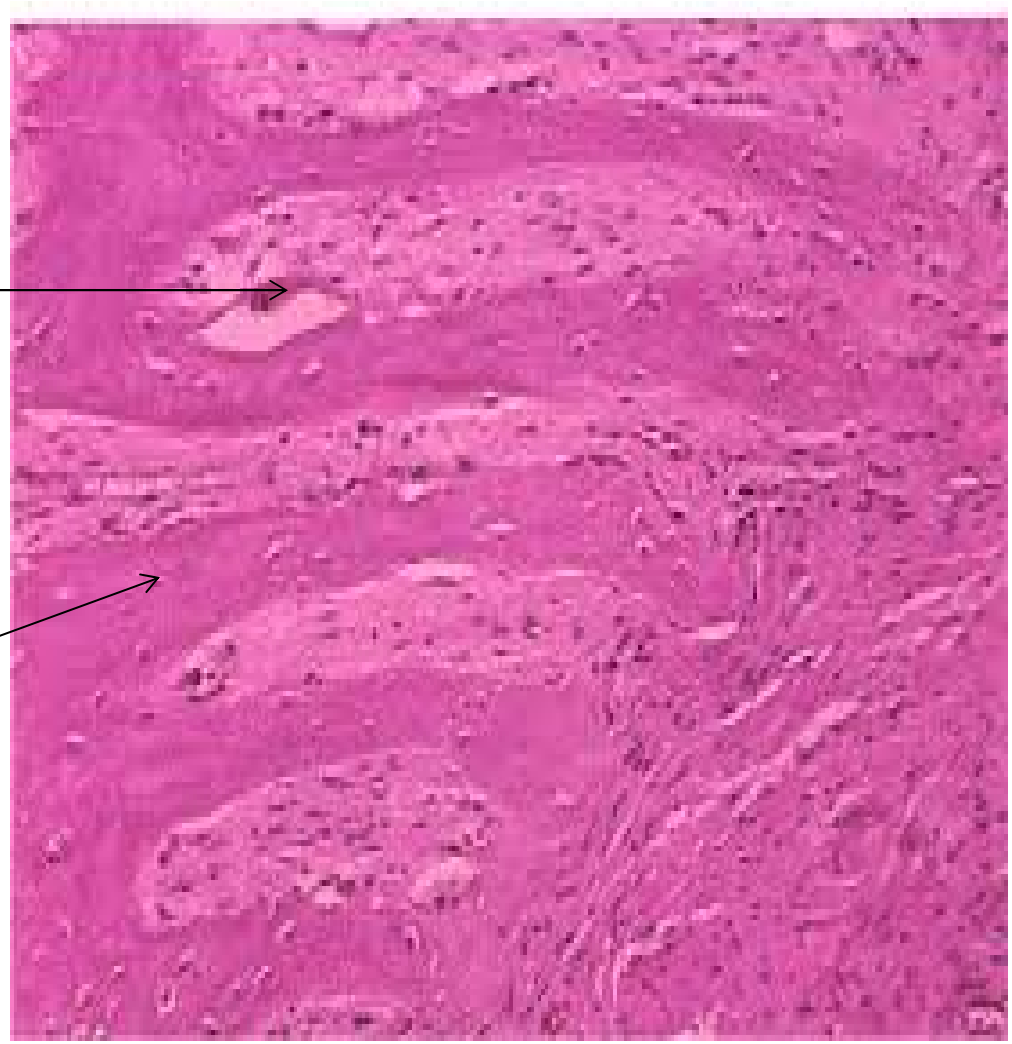

Acute O.M.

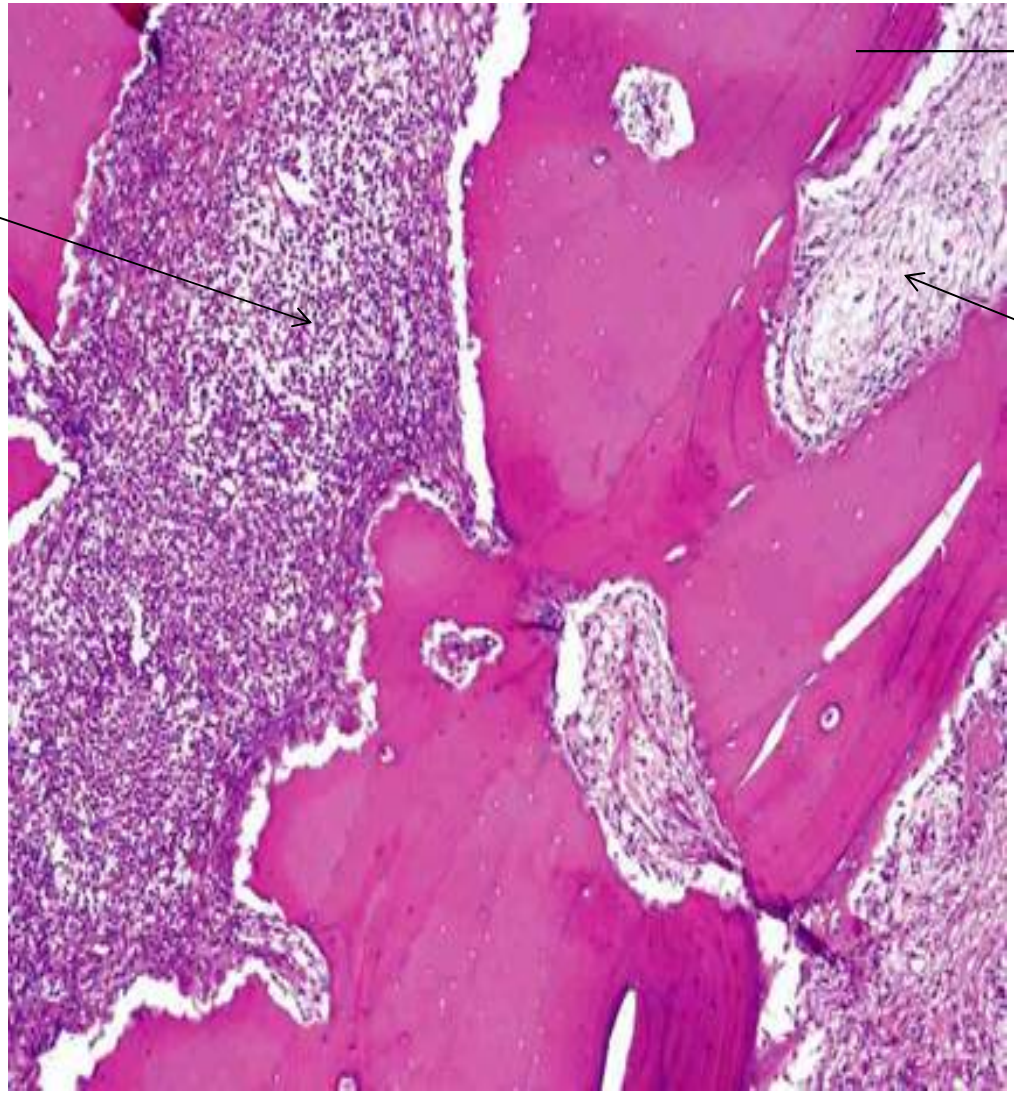
Neutrophils
Infiltrate
Dead bone
sequestrum
Fibrous
marrow

PROLIFERATIVE PERIOSTITIS

HISTOLOGY
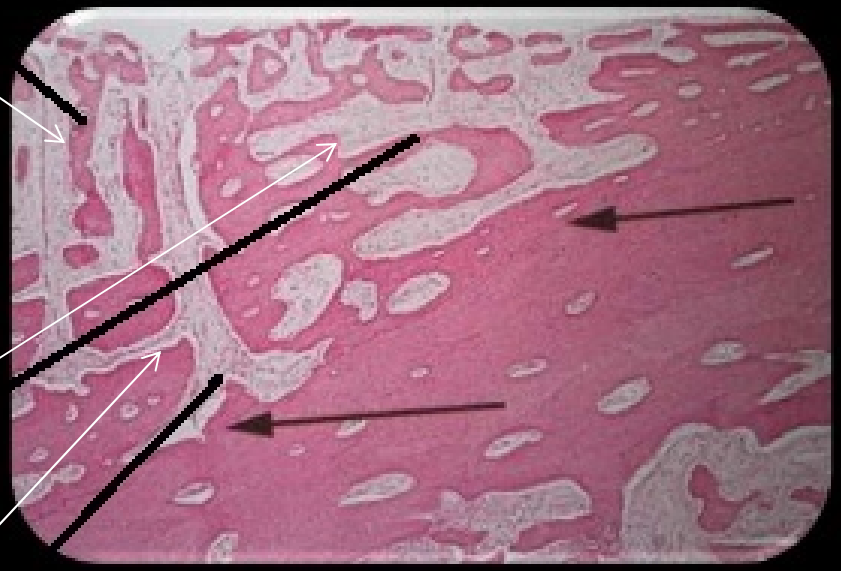
- Parallel rows of highly cellular & reactive woven bone .
- Trabeculae are frequently oriented perpendicular to surface.
- Trabeculae sometimes form an interconnecting meshwork of bone.
- Between trabeculae, uninflammed fibrous tissue is evident.